

Cavernous Hemangioma of the Left Atrium

Hemangioma cavernoso de aurícula izquierda

RICARDO LEVIN, FERNANDO LIPOVETSKY, NORMA NIEVA

These images correspond to a 54-year-old male patient who consulted for palpitations and unusual chest pain, and was diagnosed cavernous hemangioma of the left atrium. After echocardiographic finding of the mass –suspected myxoma–, the patient underwent complete resection of an encapsulated tumor implanted in the atrial septum, with no mitral valve involvement. Anatomic pathology reported multiple canalicular vascular structures surrounded by endothelial cells, corresponding to the diagnosis of cavernous hemangioma. Cardiac hemangiomas represent 2.8% of benign cardiac neoplasms, and can originate in the endocardium, myocardium, epicardium, or pericardium. While these hemangiomas are benign tumors and do not cause metastasis, there are some associated risks, such as the possibility of generating syncope, strokes (due to embolization of tumor fragments), pericardial effusion and tamponade, and risk of sudden death. Surgical treatment for cavernous hemangioma is controversial, because it poses possible complications and it is difficult to previously establish the tumor line; most patients are operated on for suspected cardiac myxoma. Good long-term postoperative course suggests surgery as the first-line treatment.

Conflicts of interest

None declared (See authors' conflicts of interest forms on the website/ Supplementary Material).

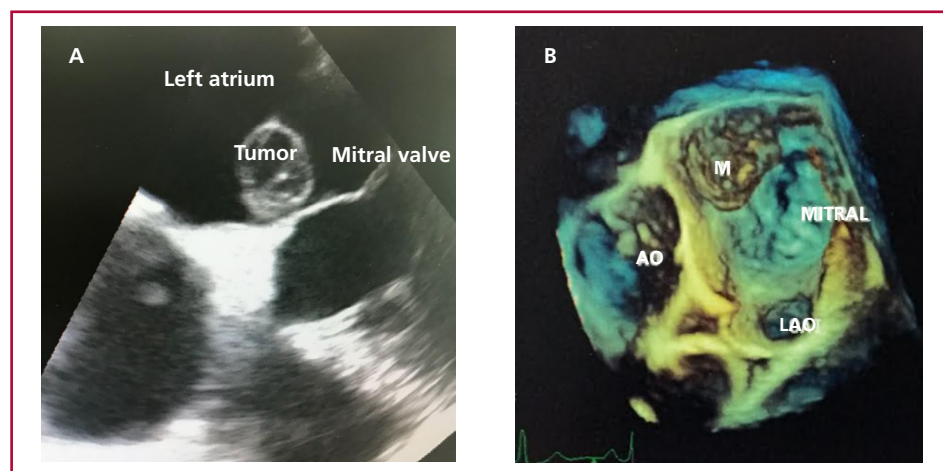


Fig. 1. Echocardiographic images. **A:** Transesophageal echocardiography. **B:** Three-dimensional echocardiography

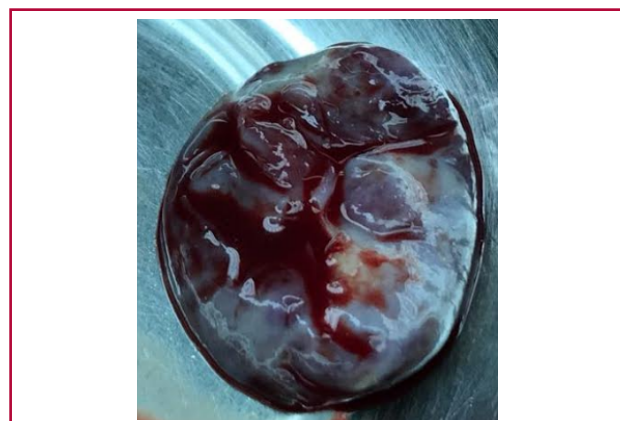


Fig. 2. Macroscopic view of the resected tumor

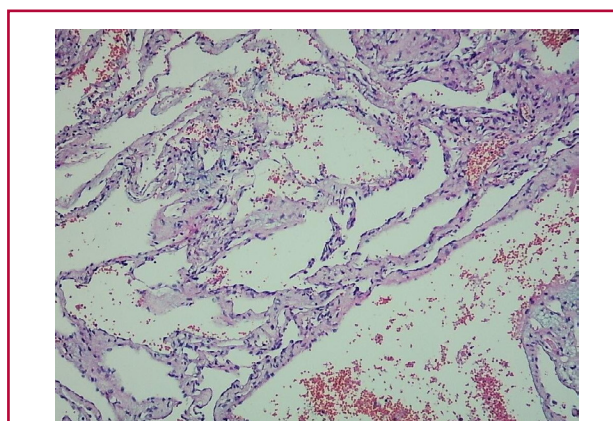


Fig. 3. Anatomic pathology of the tumor (hematoxylin-eosin)