

## Non-Fluoroscopic Mapping to Guide a Transcatheter Radiofrequency Ablation in Reciprocating Tachycardia

CLAUDIO A. MILITELLO, LUIS HALLON, RAFAEL PORCILE

Permanent junctional reciprocating tachycardia [PJRT] is a rare form of incessant supraventricular tachycardia, which substratum is a “hidden” accessory pathway of right posteroseptum habitual location with particular conduction properties (only retrograde and decremented)

We will describe one case of junctional reciprocating tachycardia in a 51 years old female patient.

Tachycardia presents a cycle length of 520 ms,  $RP > PR$  and the negative P wave in inferior leads (II, III and AVF). Inter cavity electrograms show that the earlier retrograde atrium activation is located at the septum level (proximal coronary sinus [PCS]).

In order to guide the mapping of the accessory lead, a NavX EnSite non fluoroscopic mapping system was used. This method allows three-dimensional reconstruction of the heart chamber of the study by means of a balloon catheter that has a 64 electrodes mesh, which when identifies the activation maps allows locating the arrhythmogenic foci.

Figure 1 shows the three-dimensional reconstruction of the right atrium in an oblique projection at 30°, to the left the balloon and the earlier activation zone can be observed in white; at the low inter atrium septum level. The color scheme towards violet shows the front of electric activation.

In Figure 2 a caudal projection of the right atrium can be observed; the balloon is to the left and to the right, again the earlier activation zone at the right atrium posteroseptal region.

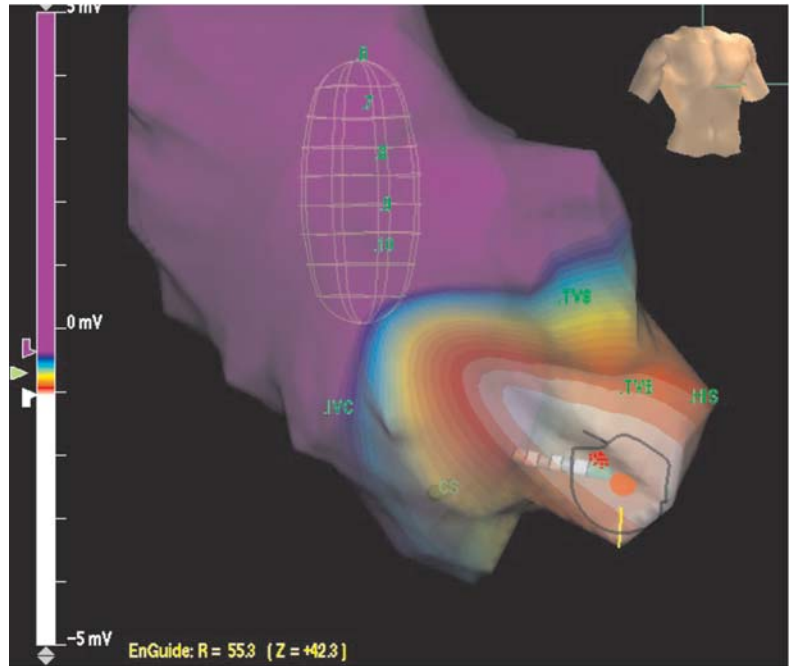


Fig. 1.

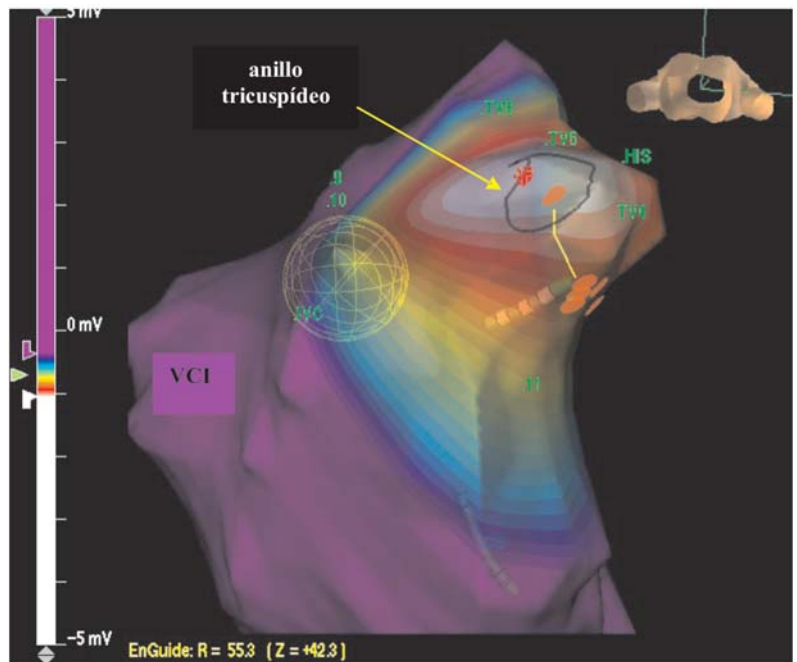


Fig. 2.