

# Multiple Intraventricular Thrombosis in Transient Apical Dyskinetic Syndrome

*Trombosis intraventricular múltiple el síndrome de discinesia apical transitoria*

VICENTE PERNIAS ESCRIG, NURIA VICENTE IBARRA, PEDRO J. MORILLAS BLASCO

These images correspond to a 71-year-old woman with no cardiovascular risk, who went to the emergency room for sudden, intense dyspnea and oppressive chest pain radiating to her left shoulder, of several hour duration after symptom onset following a situation of emotional stress. The physical exam showed BP values of 110/70 mmHg, HR of 90 bpm, bibasilar crepitant rales, and 3rd auscultation tone. Emergency ECG showed negative T waves in I, II, III, aVF, V3-V6, (panel A), and an increase in markers of myocardial injury (CK 191 U/L; troponin 0.97 ng/dL). Given the non-ST-segment elevation AMI, the patient was admitted in the intensive care unit.

The coronary angiography ruled out significant lesions. The echocardiography showed systolic dysfunction with akinesia in the apical region of the left ventricle, associated with several sharp-edged wobbling masses (anchored in the recesses of the apex and distal third of the septum) consistent with intraventricular thrombi (panels B-C-D-E). Low molecular weight heparin (LMWH) therapy was started. A magnetic resonance imaging study was performed 48 hours later, showing edema in the apex and absence of delayed enhancement, with thrombus removal.

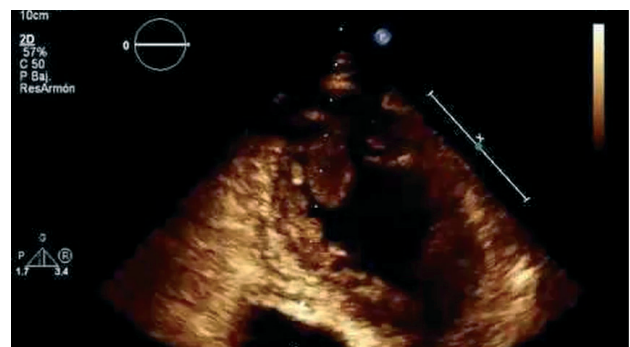
The patient was discharged with diagnosis of Takotsubo syndrome or transient apical dysfunction syndrome, treated with beta-blockers and oral anticoagulant agents. Follow-up echocardiography at 3 months showed normal systolic function and contractility of apical segments.

Intraventricular thrombosis in Takotsubo syndrome is an early and rare complication associated with abnormal myocardial contractility (2-8% of the cases), although it can also occur after contractile recovery. Its prophylaxis and treatment duration are not clearly established. In general, anticoagulation therapy for 3 months is recommended in case of intraventricular thrombus. In the absence of thrombus but with severe left ventricular dysfunction, anticoagulation for 3 months or until systolic function is normalized should be considered, always

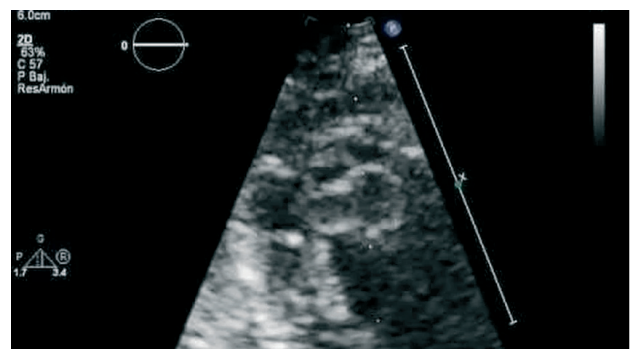
choosing the shortest option.

### Conflicts of interest

None declared (See authors' conflict of interest forms in the web/ Supplementary Material).



**Fig. 1.** Five-chamber apical projection targeting the left ventricle, showing multiple intraventricular thrombi of different sizes.



**Fig. 2.** Echocardiographic image targeting the left ventricular apex, showing several intraventricular thrombi.