

Endovascular Treatment of Aneurysms with Complex Aortic Anatomy

Tratamiento endovascular de aneurismas con anatomía aórtica compleja

LUIS MARIANO FERREIRA¹, MTSAC, MIGUEL FERRER¹, LEONELA ALOY¹, A. RICARDO LA MURA¹.

ABSTRACT

Background: Arterial anatomy is the main limiting factor for standard endovascular aortic (EVAR) approach. We present our experience for endovascular repair of complex aortic aneurysms.

Methods: This is a retrospective observational study in patients with complex aneurysms (juxta/pararenal and thoracoabdominal) treated consecutively with: fenestrated (FEVAR), branched (BEVAR), EndoAnchors (ESAR), or chimney (ChEVAR) stents. The decision of the technique was determined based on the arterial anatomy.

Results: The last 50 procedures were evaluated (6 women; mean age 71.3 years; diameter 69.6 mm; and 3 patients with complicated aneurysms), among whom 22 received FEVAR (2.8 fenestrated stents/patient), 11 BEVAR, 11 ESAR and 6 ChEVAR (1.8 chimney stents/patient). Technical success rate was 100% (absence of type I or III endoleak with adequate patency of the visceral vessels). Three patients died within the first 30 days (6%). During follow-up, 5 patients presented with renal artery occlusion, treated successfully in 4 cases. Four patients developed type IA endoleak (3 secondary ESAR and one ChEVAR), one patient IC endoleak and almost a quarter of cases type IIIB endoleak (22%, 3 out of 11 patients receiving ESAR, none of the industrial FEVAR group). Overall survival was 88.6% at one year, and 86.5% of cases were free from reoperation.

Conclusions: This is the first publication in our setting that shows a global approach to the patient with complex aortic aneurysm, according to the anatomical characteristics. These technologies already play a primary role in the treatment of these patients.

Keywords: Abdominal Aortic Aneurysm - Endovascular repair - Device modification - Durability - Long-term follow-up - Thoracoabdominal aneurysms - Juxtarenal aneurysms - Complex Aorta

RESUMEN

Introducción: la anatomía arterial es la principal limitante para el abordaje aórtico endovascular estándar. Presentamos nuestra experiencia para la reparación endovascular de aneurismas aórticos complejos.

Material y métodos: estudio observacional retrospectivo en pacientes con aneurismas complejos (yuxta/pararrenales y toracoabdominales) tratados en forma consecutiva mediante: endoprótesis fenestradas (FEVAR), ramificadas (BEVAR), con EndoAnchors (ESAR), o en chimenea (ChEVAR). La decisión de la técnica fue determinada con base en la anatomía arterial.

Resultados: se evaluaron los últimos 50 procedimientos (6 mujeres; edad promedio 71,3 años; diámetro 69,6mm; 3 pacientes con aneurismas complicados), de los cuales 22 recibieron FEVAR (2,8 fenestraciones / paciente), 11 BEVAR, 11 ESAR y 6 ChEVAR (1,8 chimeneas / paciente). La tasa de éxito técnico fue del 100% (ausencia de endoleak I o III con permeabilidad adecuada de los vasos viscerales). A 30 días 3 pacientes fallecieron (6%). Durante el seguimiento, 5 pacientes presentaron oclusión de la arteria renal, repermeabilizada en 4. Cuatro pacientes desarrollaron un endoleak tipo IA (3 ESAR secundarios y un ChEVAR), un paciente un endoleak IC y un cuarto uno IIIB (22%, 3 de los 11 ESAR, ninguno de los FEVAR industriales). En el análisis de supervivencia, la supervivencia global fue del 88,6% al año, y libre de reoperación del 86,5%.


Conclusiones: se trata de la primera publicación en nuestro medio que muestra un enfoque global del paciente con un aneurisma de aorta complejo, de acuerdo con sus características anatómicas. Estas tecnologías ya desempeñan un papel primario en el tratamiento de estos pacientes.

Palabras clave: Aneurisma de Aorta Abdominal - Tratamiento Endovascular - Modificar dispositivo - Durabilidad - Seguimiento a largo plazo - Aneurismas toracoabdominales - Aneurismas Yuxtarenales - Aorta Compleja

REV ARGENT CARDIOL 2023;91:267-272. <http://dx.doi.org/10.7775/rac.v91.i4.20561>

Received: 05/12/2023 - Accepted: 06/15/2023

Address for correspondence: L. Mariano Ferreira. Av. del Libertador 5878 4^º. CABA C1428ACQ

 <https://creativecommons.org/licenses/by-nc-sa/4.0/>
©Revista Argentina de Cardiología

¹ Division of Vascular Surgery. Clinica La Sagrada Familia. Autonomous City of Buenos Aires.

INTRODUCTION

More than 80% of infrarenal abdominal aortic aneurysms with an indication for treatment are currently excluded using an endovascular approach. (1) For this purpose, two technical alternatives have been developed: standard and complex techniques. The arterial anatomy, especially that corresponding to the visceral segment of the aorta, is the decisive factor. Endovascular repair must be sealed in a healthy aorta to provide a durable repair. Therefore, when the aneurysm has a healthy segment for infrarenal sealing, a standard approach is used, which is accompanied by a low complication rate. (2-3)

On the contrary, the development of endovascular methods for patients with visceral aortic involvement has brought about a radical change. The complex approach, indicated when the sealing zone compromises or is in contact with the segment of the aorta from which the mesenteric or renal arteries emerge, implies the use of devices that make it possible to respect the origin of these arteries. It is especially in these procedures where the results are specifically related to an advanced diagnostic and therapeutic algorithm.

We present our experience with a global technical approach (therapeutic algorithm) in endovascular repair of patients with complex aortic aneurysms.

METHODS

Patient Selection

This is a retrospective observational study that evaluated the 30-day and 3-year outcome in patients with complex aneurysms treated using an endovascular approach to place fenestrated (Fenestrated Endovascular Aneurysm Repair, FEVAR) or branched (Branched Endovascular Aneurysm Repair, BEVAR) endografts, standard endografts reinforced with EndoAnchors (EndoSuture Aneurysm Repair, ESAR), or standard endografts with parallel or chimney stents to preserve the visceral arteries (Chimney Endovascular Aneurysm Repair, ChE-VAR). The decision of the technique was determined based fundamentally on arterial anatomy. Emergency patients were excluded.

Definitions and End Points

Aortic aneurysm with complex anatomy is a juxtarenal, pararenal, paravisceral, or thoracoabdominal aortic aneurysm (TAAA), which, per instructions for use of a standard endovascular graft, is not a candidate for exclusion by placement of only a standard infrarenal bifurcated endograft (EVAR).

Three fundamental algorithms have been used for the diagnosis and treatment of these patients.

Patients were evaluated by CT angiography with intravenous injection of contrast, except in those with creatinine clearance less than 30 ml/min, in whom the intra-arterial route with an aortic catheter was preferred to reduce the amount of contrast injected (less than 60 ml for thoracoabdominal studies). Various imaging tools were also used during surgery to reduce the amount of contrast and radiation: image fusion (Vessel Navigator, Azurion/Allura Xper FD20, Philips Healthcare), intraoperative cone beam tomography (Xpert-CT, Philips) and intravascular ultrasound (IVUS Vulcano, Philips).

Patients were evaluated with CT angiography before discharge to verify aneurysm exclusion, device integrity, and

aortic collateral vessel patency. Doppler and CT scan without contrast were performed only in those with renal failure.

In the absence of endoleak, follow-up controls were performed by CT angiography and Doppler at 6 and 12 months and then annually, whereas in the presence of endoleak, follow-up was carried out according to the type of endoleak, characteristics of the patient and behavior of the aneurysmal sac.

Therapeutic algorithm

FEVAR includes a series of aortic devices that can be custom-made by a technology manufacturer (Custom Made Devices, CMD, Cook Medical, Bloomington, Ind) or by a physician in the operating room (Physician Modified Stent Graft, PMSG). Fenestrations are holes in the prosthetic material of the device that correspond to a visceral aortic branch (celiac trunk, superior mesenteric, or renal arteries), thus allowing the graft to lie more proximally than a standard configuration would admit. The orifice/fenestration of the endograft is then made to coincide with the origin of the artery to be preserved. To seal and specifically anchor the fenestration, stents are placed inside it towards the preserved artery. FEVAR was indicated in patients with a short infrarenal neck, less than 5mm in length, and visceral aortic diameter less than 36 mm. (Fig.1)

BEVAR. Standard branched graft (Zenith t-BRANCH, Cook Medical, Denmark) consists of a tubular endograft with four caudal branches, located in the standard longitudinal and axial axes, based on CT files of patients with thoracoabdominal aneurysms. It also requires an additional stent, a bridge, to connect and seal the stent branch with the visceral vessel. It was indicated in patients with type IV thoracoabdominal aneurysms (Fig. 2).

ESAR. EndoAnchors (Heli-FX™ EndoAnchor™ system, Medtronic Inc, Minneapolis, USA), are endosutures that reinforce the contact between the endograft and the arterial wall at the neck level. The procedure involves the endovascular screwing of small helical clips, simulating the force of a hand-sewn surgical anastomosis. This approach was used in patients with the possibility of a correct apposition (contact) between the endograft and the infrarenal aorta of at least 10 mm, but with a neck over 30 mm in diameter, and conical, teardrop- or hourglass-shaped necks, all tomographic characteristics that are associated with an increased risk of mid-term dilation of the proximal neck. It was also used in previously operated patients, with growth of the aneurysmal sac due to type II endoleak and neck dilation of more than 10% or more than 32 mm in diameter.

CHEVAR. Chimney stents ensure inflow through a covered stent placed in the visceral branch parallel to the endograft. It was indicated in patients with a short neck, 5 to 10 mm but less than 28 mm in diameter, especially in high-risk patients not only for aneurysm rupture (pain or more than 70 mm) but also at high surgical risk (ASA IV).

Statistical analysis

Continuous data are presented as mean and standard deviation (SD) and categorical data as percentages. Continuous data were compared using Student's t-test or Wilcoxon's test according to their distribution. Paired data tests were used to compare the dimensions before and after the intervention. Categorical data were compared with the chi-square test or Fisher's exact test, as appropriate. Event-free survival was defined by survival analysis, with the creation of Kaplan Meier curves. Statistical analysis was performed using SPSS 25.0 software for Windows. (SPSS, Inc., Chicago, IL).

Fig. 1. From left to right. Angiographic image showing fenestrated endograft in position with introducers and guidewires placed in the renal and superior mesenteric arteries. Bottom left: Cannulation of the right renal artery. Middle: Fenestrated endograft (FEVAR) with deployed stents in the renal and mesenteric arteries. Bottom right: Final angiography. Right: Photograph of fenestrated endograft manufactured in the operation room with a central fenestration for the superior mesenteric artery.

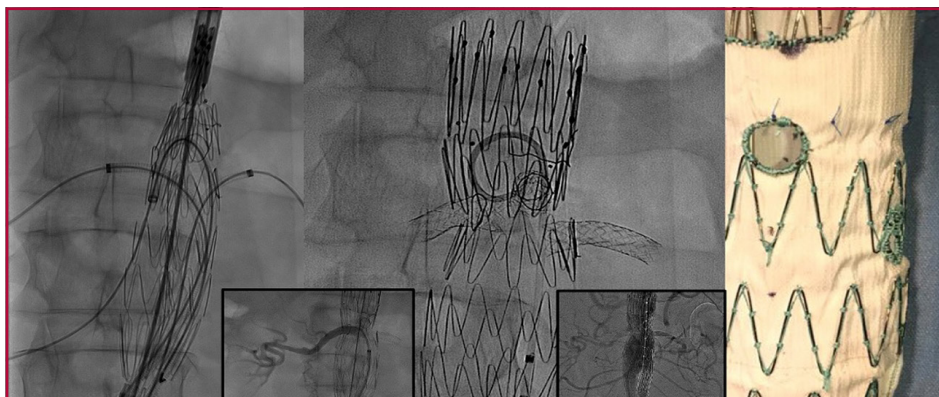
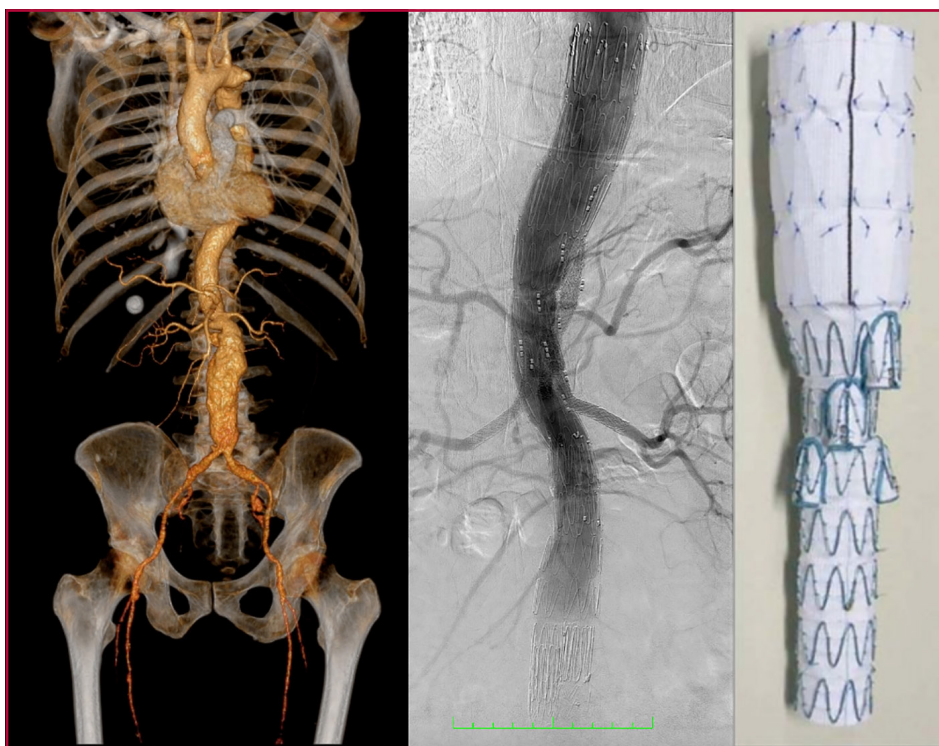


Fig. 2. Left: Computed tomography angiography of a patient with juxta-visceral aneurysm. Center: Final angiography with branched endograft towards the celiac trunk, the superior mesenteric artery and both renal arteries. Right: Photograph of the branched endograft.



RESULTS

The last 50 patients who underwent endovascular procedures for complex aortic disease, were consecutively evaluated; 44 were men (88%) and 3 (6%) had complications at the time of presentation (symptomatic or ruptured and contained aneurysm). Mean age was 71.3 ± 11.6 years, and mean aneurysmal diameter was 69.6 ± 16.6 mm (FEVAR 68.5 mm, BEVAR 66.4 mm, ESAR 72.3 mm, and ChEVAR 79, 8 mm $p=0.418$). Twelve patients (24%) presented with a previous EVAR. In this subgroup, the indication for treatment was due to type IA endoleak (n=4, 33.3%), migration (n=2, 16.7%), and proximal neck dilation (n=6, 50%).

Procedures performed included: 22 FEVAR (17 PMSG and 5 CMD), 11 BEVAR, 6 ChEVAR, and 11 ESAR.

Technical success rate was 100% without the presence of type I or III endoleak, with adequate branch patency. Three patients died during the first 30 perioperative days, one in the immediate postoperative period due to mesenteric atheroembolism (BEVAR), a second patient on day 22 due to pneumonia (patient with ruptured and contained aneurysm) and another due to ventricular tachycardia on day 8, the last two deaths secondary to ChEVAR.

Complications during follow-up

During an average follow-up of 17 months (range 1-48 months), four patients presented with type IA endoleak, three of whom received a FEVAR (all with a prior secondary ESAR, treated during follow-up for proximal neck dilation), and a fourth, with a previous ChEVAR, which was corrected by gutter embolization

and EndoAnchors placement.

Renal artery occlusion occurred in five patients (3 BEVAR and 2 PMSG). Three were corrected, a fourth high-risk patient remained asymptomatic without treatment and the fifth patient presented renal artery occlusion in an already atrophic kidney, so he also received no treatment.

In the Kaplan-Meier analysis, overall survival was 88.6% at 1 year and 77.3% at 3 years; 86.5% of cases were free of reoperation at 1 year and 61.3% at 3 years, while primary vessel patency was 91.3% at one year and 79.9% at three years.

Behavior of the aneurysmal sac

Overall, the aneurysmal sac underwent a non-significant reduction from $68.3 \text{ mm} \pm 15.6 \text{ mm}$ to $66.9 \text{ mm} \pm 17.6 \text{ mm}$ ($p=0.69$). However, knowing the small number of patients in the series, the tomographic information was disaggregated by procedure. Patients with BEVAR developed sac narrowing from $64.9 \text{ mm} \pm 8.12 \text{ mm}$ to $59 \text{ mm} \pm 8.2 \text{ mm}$ ($p=0.14$) and those with FEVAR from $60.17 \text{ mm} \pm 11.1 \text{ mm}$ to $54.17 \text{ mm} \pm 9.9 \text{ mm}$ ($p=0.31$). Specifically, aneurysmal sac enlargements developed in type IA endoleak patients who were repaired and three in type II endoleak patients currently under observation.

DISCUSSION

This series shows the experience of a center specialized in the treatment of patients with aortic aneurysms. Supported by a selection based on anatomical and clinical-surgical criteria, it is the first publication in our setting that shows a global approach to the patient with complex aortic aneurysm. The application of a well-established protocol made it possible to treat this group of patients at high surgical risk, even during the pandemic, with a perioperative morbidity and mortality rate similar to international standards.

It is estimated that 50% of patients with abdominal aortic aneurysms are not candidates for endovascular repair with the devices currently available on the market due to their unfavorable anatomy. (4) This includes patients with short or angled necks, aneurysmal extension to the internal iliac artery, or aneurysmal involvement of the juxtarenal, paravisceral, and thoracoabdominal aorta (complex aorta). Good surgical candidates can tolerate conventional open surgery. (5,6) However, in a recent presentation at the Charing Cross International Symposium in London on April 27, 2023, the surgical team from the University of Brescia, after matching covariates from 204 patients with thoracoabdominal aneurysms, determined that 30-day mortality after open surgery was 13% vs. 5% for complex endovascular treatment; paraplegia was 10% vs. 3%, severe respiratory complications 18% vs. 7%, cardiac complications 42% vs. 26% and severe renal 27% vs. 6% for endovascular treatment. This shows a real world with current statistics, advanced technology and a surgical team with experience in both approaches.

Complex endovascular aortic techniques were designed to extend the proximal sealing zone from the infrarenal segment to the juxta or suprarenal aorta, thus avoiding the limitation of the absence or short length of the infrarenal aortic segment. From the moment we started in 2011 the first option for these patients has been and remains the placement of a fenestrated endograft (FEVAR). Since then, evolution has meant better patient selection, innovative changes in endograft design, significant developments in imaging technology, and the application of standardized protocols for perioperative care. It is clear that care for these patients does not begin or end in the operating room; hence the importance of multidisciplinary care, on which the overall success of the procedure depends.

Fenestrated grafts specifically need to be custom assembled. Arterial anatomy is unique for each patient, and precise contact between graft orifice and the origin of the artery to be preserved is required. That information is obtained from the CT scan and must be transferred to a design to build the endograft. The industrial production of these devices (*Cook Medical* in our case) implies a certain delay in their availability (authorization time, production, and transfer) that may be too long for patients with urgent needs (aneurysms of more than 7 cm, symptomatic or ruptured). The way to respond to this problem was to train in endograft manufacturing, but fenestrated in the operating room, which has the enormous advantage of the almost immediate availability of a custom-made endograft. (7) For this purpose, two members of the team were trained at the Mayo Clinic (Rochester, Minnesota). This allowed us to design these endografts with variables such as number, location, and fenestration size or to design them to be cannulated for a femoral or subclavian approach. Thus, we can access from the cranium to caudally oriented vessels, and also avoid placing a bulky introducer in a femoral artery, which could cause limb ischemia. (8) However, published evidence and our own experience determine that this type of endografts modified in the operating room should be indicated in exceptional cases. The study presented by Dr. Oderich of the Mayo Clinic determined that the current approach has evolved from devices built in the operating room to almost exclusively company manufactured devices (CMD). These have been manufactured with greater technical success, with no mortality and with fewer serious adverse events. (9) In our series, none of the patients who received a CMD developed complications.

It is also important to emphasize the strict follow-up that these patients require. As shown in the results section, this approach is accompanied by a not negligible rate of reoperations: almost 10% of patients received a second procedure due to branch instability (occlusion or endoleak). But, most were minor surgeries and did not affect survival. (10-13)

A goal of the division was also to try to decrease the need for FEVAR in a specific group of patients.

Patients with proximal necks excluded from the instructions for use, but in whom the CT scan analysis allowed us to predict that we had a contact zone of 10 mm, were not treated with FEVAR as the first option. (14) The experience obtained with EndoAnchors allowed us an adequate seal, with no mid-term mortality or type IA endoleak, when EndoAnchors were implanted in the primary procedure. Same as in the ANCHOR registry, these results remain promising. (15) On the other hand, when they were placed before a proximal neck dilation, in some cases, the consequent dilation ended in a proximal endoleak, which had to be repaired by FEVAR.

ChEVAR was relegated to a strict anatomical and clinical indication. We are aware of the higher incidence of type IA endoleak associated with this technique, and for this reason we are very selective in its use. (16)

Finally, BEVAR was not performed in the context of dilated necks but in those evidently aneurysmal, juxta/pararenal aneurysms, where the dilated visceral aorta implied more than 5 mm of distance between the endograft and the origin of the visceral artery. (17)

Spinal cord ischemia is a devastating complication, with a known association between its incidence and mortality. (18) In 2019, we published our protocol for its prevention, analyzing 29 patients. (19) Since then, we have had no cases of early or late paraplegia.

Although current international guidelines do not directly translate into recommendations for complex treatment, it is logical and reasonable to assume that the benefits of an endovascular approach will be even greater when applied to patients with juxta, pararenal, or thoracoabdominal aneurysms. (20,21) It is well known that, due to their age and comorbidities, especially these patients have a limited life expectancy beyond surgery. It could be argued, then, that quality of life is a better metric for evaluating outcomes than survival.

Ethical considerations

The protocol was approved by the Ethics Institutional Board.

Limitations

As limitations, this was a mid-term follow-up study and in the context of a pandemic, which partially hindered patient follow-up. It is also worth highlighting the number of patients analyzed (50 patients) which, while being a representative value for our country, does not allow us to arrive to robust recommendations, but to demonstrate the possible advantages of centralizing pathologies based on experience and applied technology.

CONCLUSIONS

In conclusion, this presentation shows a global approach in which different techniques do not oppose but rather complement each other to achieve mid-

term effective and long-lasting treatment in patients with complex aortic aneurysms. The goal is not to compare the techniques, since they have different indications, but rather to seek a final result, which is the minimally invasive treatment of patients with great technical complexity.

Conflicts of interest

None declared.

(See authors' conflict of interests forms on the web).

Financing

None.

REFERENCES

- Lederle FA, Freischlag JA, Kyriakides TC, Padberg FT Jr, Matsumura JS, Kohler TR, et al. Outcomes following endovascular vs open repair of abdominal aortic aneurysm: a randomized trial. *JAMA* 2009;302:1535-42. <https://doi.org/10.1001/jama.2009.1426>
- Huang Y, Glovinsky P, Oderich GS, Duncan AA, Kalra M, Fleming MD y col. Outcome after open and endovascular repairs of abdominal aortic aneurysm in matched cohorts using propensity score modeling. *J Vasc Surg* 2015;62:304-311. <https://doi.org/10.106/jvs.2015.02.039>.
- Lai BK, Zhou W, Li Z, Kyriakides T, Matsumura J, Lederle FA, et al; OVER Veterans Affairs Cooperative Study Group. *J Vasc Surg* 2015;62:1394-404. <https://doi.org/10.1016/j.jvs.2015.02.003>.
- Escobar GA, Oderich GS, Farber MA, de Souza LR, Quinones-Baldrich WJ, Patel HJ, et al; NACAAD Investigators. Results of the North American Complex Abdominal Aortic Debranching (NACAAD) Registry. *Circulation*. 2022;146:1149-58. <https://doi.org/10.1161/CIRCULATIONAHA.120.045894>.
- Locham S, Dakour-Aridi H, Nejim B, Dhaliwal J, Alshwaily W, Malas M. Outcomes and cost of open versus endovascular repair of intact thoracoabdominal aortic aneurysm. *J Vasc Surg* 2018;68:948-55.e1. <https://doi.org/10.1016/j.jvs.2018.06.211>
- Locham S, Dakour-Aridi H, Bhela J, Nejim B, Havana Challa A, Malas M. Thirty-Day Outcomes of Fenestrated and Chimney Endovascular Repair and Open Repair of Juxtarenal, Pararenal, and Suprarenal Abdominal Aortic Aneurysms Using National Surgical Quality Initiative Program Database (2012-2016). *Vasc Endovasc Surg* 2019;53:189-98. <https://doi.org/10.1177/1538574418819284>.
- Zettervall SL, Tenorio ER, Schanzer A, Oderich GS, Timaran CH, Sweet MP. Secondary interventions after fenestrated/branched aneurysm repairs are common and non detrimental to long-term survival. *J Vasc Surg* 2022;75:1530-8. <https://doi.org/10.1016/j.jvs.2021.11.074>
- Timaran CH, Oderich GS, Tenorio ER, Farber MA, Schneider DB, Schanzer A, et al; Aortic Research Consortium. Expanded Use of Preloaded Branched and Fenestrated Endografts for Endovascular Repair of Complex Aortic Aneurysms. *Eur J Vasc Endovasc Surg*. 2021;61:219-26. <https://doi.org/10.1016/j.ejvs.2020.11.001>.
- Oderich GS, Ribeiro MS, Sandri GA, Tenorio ER, Hofer JM, Mendes BC, et al. Evolution from physician modified to company-manufactured fenestrated-branched endografts to treat pararenal and thoracoabdominal aortic aneurysms. *J Vasc Surg* 2019;70:31-42. <https://doi.org/10.1016/j.jvs.2018.09.063>.
- Schanzer A, Greenberg RK, Messina L. Predictors of abdominal aortic aneurysm sac enlargement after endovascular repair. *Circulation* 2011;123:2848-55. <https://doi.org/10.1161/CIRCULATIONAHA.110.014902>
- Chait J, Tenorio ER, Mendes BC, Barbosa Lima GB, Marcones GB, Oderich GS. Impact of gap distance between fenestration and aortic wall on target artery instability following fenestrated-branched endovascular aortic repair. *J Vasc Surg* 2022 Jul;76(1):79-87. <https://doi.org/10.1016/j.jvs.2022.01.135>
- Ferreira LM, Ferrer M, Zambrano A, Cohen Arazi H, La Mura R. Marcadores a largo plazo para la endofuga tipo I proximal. <https://doi.org/10.20960/angiologia.00040>.

13. Konstantinou N, Kölbel T, Dias NV, Verhoeven E, Wanhainen A, Gargiulo M, et al. Revascularization of occluded renal artery stent grafts after complex endovascular aortic repair and its impact on renal function. *J Vasc Surg.* 2021;73:1566-72. <https://doi.org/10.1016/j.jvs.2020.09.036>.
14. Jordan WD, Mehta M, Varnagy D, Moore WM, Arko FR, De Vries JP. Results of the ANCHOR prospective, multicenter registry of EndoAnchors for type Ia endoleaks and endograft migration in patients with challenging anatomy. *J Vasc Surg* 2014;60:885-92. <https://doi.org/10.1016/j.jvs.2014.04.063>
15. Wu WW, Swerdlow NJ, Dansey K, Shuja F, Wyers MC, Schermerhorn ML. Surgical Treatment patterns and clinical outcomes of patients treated for expanding aneurysm sacs with type II endoleaks after endovascular. *J Vasc Surg* 2021;73:484-93. <https://doi.org/10.1016/j.jvs.2020.05.062>
16. Fazzini S, Martinelli O, Torsello G, Austermann M, Pipitone MD, Torsello GF, et al. Eur the PROTAGORAS 2.0 study to identify sizing and planning predictors for optimal outcomes in abdominal chimney endovascular *J Vasc Endovasc Surg* 2021; 61:591-602. <https://doi.org/10.1016/j.ejvs.2020.11.019>.
17. Tsilimparis N, Bosiers M, Resch T, Torsello G, Austermann M, Rohlfes F, et al. Two-year target vessel-related outcomes following use of off-the-shelf branched endografts for the treatment of thoracoabdominal aortic aneurysms. *J Vasc Surg.* 2023;S0741-5214(23)01017-0. <https://doi.org/10.1016/j.jvs.2023.03.498>.
18. Aucoin VJ, Eagleton MJ, Farber MA, Oderich GS, Schanzer A, Timaran CH, et al. Spinal cord protection practices used during endovascular repair of complex aortic aneurysms by the U.S. Aortic Research Consortium. *J Vasc Surg.* 2021;73:323-30. <https://doi.org/10.1016/j.jvs.2020.07.107>
19. Ferreira LM, Ferrer M, La Mura R. Staging Procedures, Cerebrospinal Fluid Drainage, Selective Neuromonitoring, and Use of Conduits During Complex Endovascular Aortic Repair in Patients With High Risk of Spinal Cord Injury. *J Vasc Surg* 2019;70:149. <https://doi.org/10.1016/j.jvs.2019.08.098>
20. Chaikof EL, Dalman RL, Eskandari MK, Jackson BM, Lee WA, Mansour MA, et al. The Society for Vascular Surgery practice guidelines on the care of patients with an abdominal aortic aneurysm. *J Vasc Surg.* 2018;67:2-77.e2. <https://doi.org/10.1016/j.jvs.2017.10.044>.
21. Wanhainen A, Verzini F, Van Herzelee I, Allaire E, Bown M, Cohnert T, et al. Editor's Choice - European Society for Vascular Surgery (ESVS) 2019 Clinical Practice Guidelines on the Management of Abdominal Aorto-iliac Artery Aneurysms. *Eur J Vasc Endovasc Surg.* 2019;57:8-93. <https://doi.org/10.1016/j.ejvs.2018.09.020>.